

Clinical assessment of copper oxide nanoparticles and black elderberry extract in therapy of avian pathogenic *Escherichia coli* infection in SPF chicks

Sawsan S. Elbasuni^{1*}, Mohamed A. Abaza¹, Marwa A. Abdelmagid², Osama Ahmed³, Ahmed Maher⁴, Mai O. Nada⁵, Marwa I. Abdel Haleem¹

¹Department of Avian and Rabbit Diseases, Faculty of Veterinary Medicine, Benha University, Benha 13736, Egypt.

²Reference Laboratory for Veterinary Quality Control on poultry production, Animal Health Research Institute, Agriculture Research Center, Giza, Egypt.

³Department of Anatomy and Embryology, Faculty of Veterinary Medicine, Benha University, Benha 13736, Egypt.

⁴Department of Zoonotic diseases, Veterinary Research Institute, National Research Centre, Giza, Egypt.

⁵Department of Veterinary Pharmacology, Animal Health Research Institute (AHRI)-Benha Branch, Agriculture Research Center (ARC), Benha 13518, Egypt.

ARTICLE INFO

Received: 03 November 2023

Accepted: 15 December 2024

*Correspondence:

Corresponding author: Sawsan S. Elbasuni
E-mail address: Sawsan.mohamed@fvtm.bu.edu.eg

Keywords:

Colibacillosis
CuO-NPs
Black elderberry extract
Chick
Microbial count
Histopathology

ABSTRACT

Escherichia coli (*E. coli*) infections pose significant health risks to poultry and humans globally. In the face of antibiotic-resistant strains, metal oxide nanoparticles and plant extracts have emerged as promising alternatives. This study evaluated the effectiveness of copper oxide nanoparticles (CuO-NPs) and black elderberry extract (BEE) against *E. coli* O78 infection in specific pathogen-free chicks. The birds were divided into four groups: a negative control NC, a positive control (PC; challenged with *E. coli* O78), CuO-NPs treatment post-challenge, and BEE treatment post-challenge. Various parameters, including clinical signs, organ lesions, bacterial load, biochemical markers, and histopathology, were assessed. Both CuO-NPs and BEE demonstrated a reduction in clinical morbidity, organ damage, and *E. coli* counts compared to the PC. However, BEE exhibited slightly greater efficacy in alleviating liver and kidney dysfunction. Overall, CuO-NPs and BEE hold therapeutic potential against avian colibacillosis, likely acting through antimicrobial and immunomodulatory mechanisms. These findings underscore the potential of bio-based nanoparticles and plant extracts as safer, multi-modal alternatives to antibiotics for avian colibacillosis. Further optimization and mechanistic studies are needed to support their clinical application.

Introduction

The persistent use of antibiotics has raised concerns due to its adverse impacts on the environment, host immune suppression, the emergence of drug-resistant bacteria, and the presence of antibiotic residues in meat byproducts (Elmowalid *et al.*, 2019). *Escherichia coli* (*E. coli*) are a significant foodborne pathogen (Chodkowska *et al.*, 2022), that is accountable for a range of complex infections in both humans (mild to severe watery diarrhea, urinary tract infections, peritonitis septicemia, Gram-negative bacterial pneumonia, and neonatal meningitis (Hammerum and Heuer, 2009; Allocati *et al.*, 2013), and animals on a global scale. The occurrence of avian colibacillosis is attributed to the presence of enterotoxigenic *E. coli*, particularly serogroups O1, O2, and O78 (Ateya *et al.*, 2019). The occurrence of this condition has been seen in many breeds and age groups of chickens (Wang *et al.*, 2017). According to Ateya *et al.*, (2019); Masood *et al.*, (2021), several strains of *E. coli* O78 have the ability to establish themselves in both the gastrointestinal and respiratory tissues, leading to the development of multiple disorders within and beyond the intestines. The primary clinical manifestations of *E. coli* infection in chickens involve a range of conditions, such as acute colisepticaemia resulting in abrupt mortality, as well as sub-acute fibrinopurulent serositis occurring between 2 to 8 weeks of age (Hashem *et al.*, 2020). This disease is additionally related to various conditions, including enteritis, arthritis, septicemia, and complicated airsacculitis (Hashem *et al.*, 2020). Consequently, the global chicken industry experiences substantial economic losses annually as a result of the disease's high morbidity rates, varying mortality rates, reductions in egg production, condemnations of carcasses, and diminished bird performance (Wang *et al.*, 2017; Ateya *et al.*, 2019).

The prolonged and consistent utilization of antibiotics can lead to adverse environmental consequences, immunosuppression in the host, the evolution of microorganisms resistant to several drugs, including those commonly employed in human medicine, and the presence of antibiotic residues and harmful compounds in meat byproducts (Elmowalid *et al.*, 2019). The emergence of antibiotic-resistant organisms causing colibacillosis escalated the public health concerns in numerous countries as this threatens the effective treatment of *E. coli* infections in humans (Hammerum and Heuer, 2009; Allocati *et al.*, 2013), hence requiring the investigation of alternative therapeutic methods and innovative tactics for addressing *E. coli* infections (Mellata, 2013).

Nanotechnology has recently gained attention in biomedical research due to its potential to address microbial infections and antibiotic resistance (Sánchez-López *et al.*, 2020). Nanoparticles are characterized as particles with sizes ranging from 1 to 100 nanometers (Sharif *et al.*, 2021). These particles possess unique physicochemical properties that distinguish them from their larger counterparts (Wang *et al.*, 2020). The distinctive characteristics of nanoparticles allow them to interact with the bacterial cell wall without the need to penetrate the cell, consequently, they may have a lesser capacity for promoting bacterial resistance compared to antibiotics (Wang *et al.*, 2017). Metal oxide nanoparticles have been identified as an efficient method for controlling bacterial infections (Jamil *et al.*, 2016). The antibacterial capabilities of copper oxide nanoparticles (CuO-NPs) have attracted considerable interest, primarily because copper is a cost-effective metal with lower toxicity (Rubilar *et al.*, 2013). The nanoparticles exhibit a high surface-to-volume ratio, which results in heightened reactivity and higher antibacterial efficacy when compared to traditional copper-based compounds, furthermore, it is worth noting that CuO-NPs have unique physicochemical characteristics, such as a significant surface charge (Nikolova and Chavali, 2020). This particular feature

enables them to effectively engage with bacterial cell membranes and induce disruptions in cellular integrity (Nikolova and Chavali, 2020). Previous studies have provided evidence on the efficacy of CuO-NPs in combating a range of bacterial strains, including those that have developed resistance to conventional drugs (Sharif *et al.*, 2021). Nevertheless, the extent to which they can be utilized as a therapeutic intervention for *in vivo E. coli* infections has not been extensively investigated.

In recent years, research has been an increasing interest in exploring the antibacterial effects of natural substances and plant-based extracts. These compounds possess a wide range of chemical structures and biological activity that can be explored for their potential medicinal applications. According to a recent study conducted by Khan *et al.* (2022), it has been found that the consumption of darkly colored fruits may enhance the body's defense mechanisms against infectious pathogens. In a study conducted by Mohammadsadeghi *et al.* (2013), it was determined that elderberry extracts possess antibacterial capabilities that are effective against a variety of bacteria, encompassing both Gram-positive and Gram-negative strains. An example of a chemical that is of interest is sambucol, which is a standardized extract of black elderberry obtained from the *Sambucus nigra* plant (Najmi *et al.*, 2022). Black elderberries extract has historically been employed for its therapeutic features, encompassing its antibacterial and immunomodulatory characteristics (Mohammadsadeghi *et al.*, 2013; Młynarczyk *et al.*, 2018). The antibacterial characteristics of black elderberries extracts have been shown to be associated with its active constituents, including flavonoids, phenolic acids, and anthocyanins, which exhibit antimicrobial and antioxidant capabilities (Mohammadsadeghi *et al.*, 2013). Moreover, studies have demonstrated that black elderberries extract exhibits immunomodulatory properties by augmenting both the innate and adaptive immune responses (Młynarczyk *et al.*, 2018). The immunomodulatory action exhibited by this substance is believed to have a role in its efficacy against bacterial infections, as it is thought to enhance the host's defense mechanisms (Młynarczyk *et al.*, 2018). However, there is a lack of comprehensive research on the precise impacts of black elderberries extract on avian *E. coli* infections.

In light of these considerations, our study aimed to comprehensively investigate the effects of CuO-NPs and black elderberries extract on *E. coli* infection in specific pathogen-free (SPF) chicks through a comparative *in vivo* analysis. This research may provide valuable insights into the development of novel therapeutic approaches for combating *E. coli* infections, offering promising alternatives to conventional antibiotics.

Materials and methods

Copper Oxide Nanoparticles preparation

A chemical reduction method was used for preparation of The CuO-NPs following the procedure detailed by Khan *et al.* (2016). In brief, 0.1M copper sulfate pentahydrate was introduced into 120 mL of a 1.2% starch solution while vigorously stirring for 30 minutes. Subsequently, 50 mL of 0.2M ascorbic acid was added, and the mixture was stirred rapidly. This was followed by the gradual addition of 30 mL of 1M sodium hydroxide. The resulting solution was then heated to 80°C and maintained at this temperature for 2 hours with continuous stirring until a noticeable change in color to yellow ochre was observed. The CuO-NPs were subsequently recovered through filtration, washed thoroughly with deionized water and ethanol, and finally dried at room temperature. The purity of phase and crystalline size of the prepared CuO-NPs were determined by X-ray Diffraction (XRD) Analysis using a (PAN-analytical), with Cu K-alpha wavelength radiation (Scherrer, 2013).

Experimental birds and design

A total of 120 one-day-old White Leghorn Specific Pathogen-Free (SPF) chicks were acquired from the Agricultural Research Center, Fay-

oum, Egypt. These chicks were accommodated in the laboratory animal research center at Benha University's Faculty of Veterinary Medicine, Egypt. These chicks were randomly divided into four groups, each consisted of 30 chicks with five replicates (n=6 per replicate). The experimental groups included; 1) Negative control group (NC): Not treated and not challenged; 2) Positive control group (PC): Challenged with *E. coli* O78; 3) CuO-NPs treated group (CNP): Challenged and treated with CuO-NPs (1 g/lit. DW) for 5 days; and 4) Black Elderberry extract treated group (BEE): Challenged and treated for 5 days with black elderberry extract (0.15 g/lit. DW), obtained from Pharmicare, Inc., San Diego, USA.

At 14 days of age, all birds of all experimental groups were weighed. Then, the birds in NC group were received 1 ml of normal saline solution and kept isolated during the experiment. Each bird in the challenged groups (PC; CNP & BEE) was orally inoculated according to El-Boushy *et al.* (2006) with *E. coli* O78 isolate (1.0×10^8 colony forming unit/ml) that was friendly obtained from Microbiology Department, Animal Health Research Institute, Egypt. Clinical signs and mortalities were assessed and recorded on a daily basis for all experimental groups. Later at the 7-day post-challenge (dpc), blood samples (n=5 per group) were aseptically collected, and centrifuged at 3,000 rpm for 10 minutes, after which the serum was carefully separated and preserved at -20°C until subjected to further biochemical analysis. Moreover, five birds from each experimental group were weighed and then humanely euthanized to estimate the following parameters:

Postmortem examination and lesion scoring

The humanely euthanized chicks were examined macroscopically and the pathological changes in the different organs were recorded and the lesions were scored following to Goren (1978): depending on the lesion severity as (0-2) in heart, pericardium, peritoneum, liver and intestine; (0-4) in air sacs and (0-5) in lungs. Moreover, the livers from the euthanized birds were weighted to calculate their relative weight.

E. coli quantification

Lung tissue samples (n=5 per group) were aseptically excised from euthanized birds. The samples were subsequently subjected to a tenfold dilution by weight using sterile 0.90% physiological saline solution. Mechanical agitation was applied for 1 minute to ensure homogeneity. Subsequently, all samples underwent serial dilution to achieve appropriate concentrations for plating, as per the procedures outlined by Pham *et al.* (2023).

Histopathological examination

Tissue sections from the lungs, liver, and intestine (5 specimens per group) were collected from the euthanized birds, preserved in formalin (20%), and later embedded in paraffin. Subsequently, sections with a thickness of 3 µm were prepared and subjected to Hematoxylin and Eosin (H&E) staining, following the established protocols described by (Bancroft and Gamble, 2008) followed by histopathological examination. The scoring assessment was performed over 5 randomly selected fields of different tissue sections using 10× and 20× objective lenses using a light microscope (Leica DM3000; Leica Microsystems GmbH., Germany) and applied according to the (0-5) scoring of Gibson-Corley *et al.* (2013) using the following criteria: 1) normal histological structure, 2) mild pathological alterations, 3) mild to moderate pathological changes, 4) moderate to severe pathological changes, and 5) severe pathological changes (Gibson-Corley *et al.*, 2013).

Biochemical analysis

The study encompassed the evaluation of serum markers associated

with liver and kidney functions. The enzymatic activities of glutamate-oxaloacetate transaminase (GOT) and glutamate-pyruvate transaminase (GPT) were quantified through colorimetric assays conducted at a wavelength of 505 nm. The assays were executed utilizing Sigma test kits, as per the procedure described by Melesse *et al.* (2011). Moreover, levels of creatinine and urea were determined following the protocol outlined by Tovar *et al.* (2002).

Ethical approval

All animal procedures in this study adhered to the guidelines set by the Animal Welfare Committee at Benha University's Faculty of Veterinary Medicine (BUFVTM 19-04-23).

Statistical analysis

All data were analyzed as a completely randomized design by one-way ANOVA using the statistical application SPSS version 20.0 for Windows (SPSS, Inc., Chicago, IL, USA). Tukey's post hoc test ($p < 0.05$) was conducted to determine the significance level between the experimental groups.

Results

The synthesized CuO-NPs underwent thorough characterization via X-ray diffraction (XRD) analysis, employing a (PAN-analytical), with Cu K-alpha wavelength radiation. The XRD pattern (Figure 1), displayed distinct diffraction peaks at 2θ values of 15.06° , 17.16° , 18.33° , 23.23° , 29.92° , 36.59° , 42.47° , 43.42° , 44.68° , 50.41° , 61.54° , and 73.73° , which corresponded to the (110), (111), (111), (200), (-220), (220), (311), (-311), (220), (-311), (222), and (-222) crystallographic planes of monoclinic CuO (according to JCPDS #48-1548). These observations unequivocally confirmed the formation of pure-phase CuO-NPs. Furthermore, the average crystallite size was determined to be approximately 12 nm through the application of the Scherer equation.

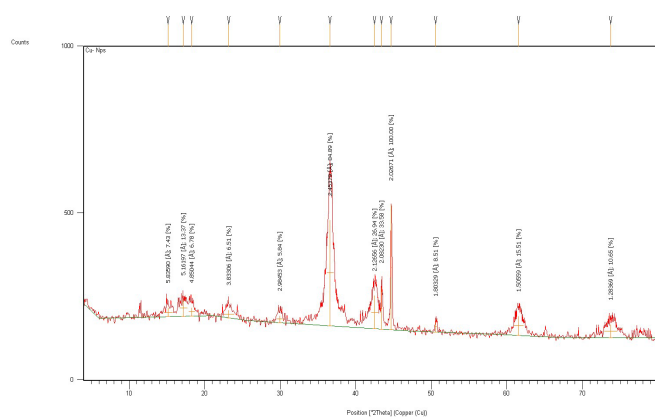


Fig. 1. XRD pattern of synthesized CuO nanoparticles.

Body weight (BW) and weight gain (WG) significantly ($p < 0.05$) decreased in the PC group (510 ± 9.08 and 105.8 ± 5.41) in comparison to the NC group (542 ± 3.74 and 136.6 ± 5.22) as shown in Table 1. The treated challenged groups, CNP and BEE, showed improvement in BW and WG in comparison to the PC group ($p < 0.05$). BW and WG of birds in BEE group come close to the values recorded in the NC group while the best values recorded in CNP group as 590 ± 9.08 and 183.8 ± 7.91 , respectively.

Clinical signs recorded in the *E. coli*-challenged chicks were ruffled feathers, inappetence, labored breathing with gargling sounds, and diarrhea. In the PC group, all birds suffered firstly from diarrhea at 2 dpc after respiratory symptoms were recorded at 3 dpc. As well as they were in poor performance observing a significant reduction in body weight and

weight gain. Otherwise, chicks in the CNP group had good performance with no signs of diarrhea, although respiratory symptoms appeared lately at 5 dpc. As for the BEE group, no respiratory symptoms appeared, and diarrhea was recorded lately but to a lesser extent than what was recorded in the PC group in addition to being in good condition resembling the NC group. There were no recorded mortalities in all experimental groups.

Table 1. Effect of CuO-NPs and black elderberry extract on body weight and weight gain of *E. coli* challenged SPF chicks.

Item / Group*	NC	PC	CNP	BEE
BW at 0 dpc.	405.4±1.96	404.2±1.83	406.2±1.46	404.8±1.88
BW at 7 dpc	542.0±3.74 ^b	510±4.47 ^c	590.0±9.08 ^a	558.0±4.90 ^b
WG at challenge time	136.6±5.22 ^b	105.8±5.42 ^c	183.8±7.91 ^a	153.2±6.06 ^b

Means with different superscripts (^{a, b, c, and d}) within a column are profoundly different at $p < 0.05$. Values are given as the mean ($n = 5$) ±SE. Values are given as the mean ($n = 5$) ±SE. *NC: non-treated non-challenged group; PC: Challenged with *E. coli* O78; CNP: challenged with *E. coli* O78 and treated with CuO-NPs in drinking water (1 g/L) 5 days after challenge; and BEE: challenged with *E. coli* O78 and treated with BEE in drinking water 0.15 g/ liter for 5 days after challenge.

Postmortem findings of the humanly euthanized chicks in the PC group at 7 dpc revealed pericarditis, air sacculitis, hepatitis, enteritis, and straw-colored fluid in the abdominal cavity. Otherwise, PM findings of the examined organs in the treated groups with a somewhat apparently healthy or mild degree especially the liver, and intestine in the CNP group and heart, lungs, and air sacs in the BEE group. A significant impact of CuO-NPs and BEE treatment on visceral organ health following an *E. coli* O78 challenge clearly observed with minimal lesion scoring (Table 2) as well as the non-treated, non-challenged group (NC) served as a baseline with minimal organ damage, while the challenged group (PC) exhibited substantial organ lesions. Notably, the group treated with CuO-NPs showed improvements, including the absence of lesions in the heart and liver. Moreover, the group treated with BEE displayed the lowest lesion-scoring values and an absence of lesions in major organs such as the heart, liver, lungs, air sacs, spleen, and peritoneum.

The relative weight of liver significantly ($p < 0.05$) increased in the PC group (3.57 ± 0.12) in comparison to the NC group (2.68 ± 0.03) as shown in Table 2. The CNP and BEE groups, showed decline ($p < 0.05$) in liver relative weight (2.13 ± 0.02 and 2.86 ± 0.01 respectively) in comparison to the PC group and come close to the values recorded in the NC group.

Table 2. Effect of CuO-NPs and black elderberry extract on macroscopic lesion score, relative liver weight and *E. coli* count in lungs of *E. coli* challenged SPF chicks.

Experimental Group*	NC	PC	CNP	BEE
Macroscopic lesion score				
Heart	0.00±0.00 ^b	0.80±0.20 ^a	0.00±0.00 ^b	0.00±0.00 ^b
Air sac	0.00±0.00 ^b	2.00±0.32 ^a	1.40±0.400 ^a	0.20±0.20 ^b
Lung	0.00±0.00 ^c	3.20±0.38 ^a	2.40±0.93 ^{ab}	0.60±0.40 ^b
Liver	0.00±0.00 ^b	2.00±0.00 ^a	0.00±0.00 ^b	0.00±0.00 ^b
Spleen	0.00±0.00 ^b	0.80±0.200 ^a	0.40±0.25 ^{ab}	0.00±0.00 ^b
Peritoneum	0.00±0.00 ^a	0.20±0.200 ^a	0.00±0.00 ^a	0.00±0.00 ^a
Intestine	0.40±0.25 ^b	1.60±0.25 ^a	0.80±0.200 ^{ab}	0.20±0.20 ^b
Relative liver weight	2.68±0.03 ^b	3.57±0.12 ^a	2.13±0.02 ^c	2.86±0.01 ^b
<i>E. coli</i> count in lung (cfu/ml)	$1.5 \times 10^3 \pm 0.29^b$	$2.5 \times 10^5 \pm 0.29^a$	$1.5 \times 10^3 \pm 0.00^b$	$0.37 \times 10^3 \pm 0.13^b$

Tukey's test represents the least profound differences between different groups at probability $p < 0.05$. Means with different superscripts (^{a, b, c, and d}) within a column are profoundly different at $p < 0.05$. Values are given as the mean ($n = 5$) ±SE.

*NC: non-treated none challenged group; PC: Challenged with *E. coli* O78; CNP: challenged with *E. coli* O78 and treated with CuO-NPs in drinking water (1 g/L) 5 days after challenge; and BEE: challenged with *E. coli* O78 and treated with BEE in drinking water 0.15 g/ liter for 5 days after challenge.

From the data illustrated in Table 2, the total colony count of *E. coli* in the lungs of the challenged birds in PC group was recorded the significant ($p < 0.05$) high value as $2.5 \times 10^5 \pm 0.29$. While in both CuO-NP and BEE groups, the *E. coli* count recorded as $1.5 \times 10^3 \pm 0.00$ and $0.37 \times 10^3 \pm 0.13$, respectively that was markedly ($p < 0.05$) lower than the PC group but even similar to or close to the values reported in the NC group.

As depicted in Table 3 and Figure 2, the SPF chicks exposed to *E. coli* O78 in the PC group exhibited notable histological alterations in the intestine, liver, and lung (4.67 ± 0.33 , 5.00 ± 0.00 , and 4.00 ± 0.58 , respectively), which were dramatically ($p < 0.05$) in comparison to the NC group. The PC group exhibited pronounced pathological alterations characterized by severe enteritis, marked by a substantial influx of inflammatory cells and fusion of intestinal villi. The observed group exhibited hyperplasia in the intestinal glands, accompanied by a constriction of the intestinal crypts. Additionally, the liver exhibited significant hepatitis, localized accumulation of inflammatory cells, congestion of hepatic sinusoids, and compressed hepatic cells. Furthermore, the lungs displayed a pronounced pneumonia, as evidenced by the significant congestion of alveolar capillaries and the presence of dense cellular exudates within the alveolar cavities.

Table 3. Effect of CuO-NPs and black elderberry extract on the histopathological scoring of *E. coli* challenged SPF chicks.

Experimental Group*	NC	PC	CNP	BEE
Intestine	1.67±0.33 ^c	4.67±0.33 ^a	2.67±0.33 ^b	2.00±0.00 ^{bc}
Liver	1.00±0.00 ^c	4.00±0.58 ^a	2.33±0.0.33 ^b	2.00±0.00 ^{bc}
lungs	2.00±0.00 ^b	5.00±0.00 ^a	2.00±0.00 ^b	2.00±0.00 ^b

Tukey's test represents the least profound differences between different groups at probability $p < 0.05$. Means with different superscripts (^{a, b, c, and d}) within a column are profoundly different at $p < 0.05$. Values are given as the mean ($n = 5$) ±SE.

*NC: non-treated non-challenged group; PC: Challenged with *E. coli* O78; CNP: challenged with *E. coli* O78 and treated with CuO-NPs in drinking water (1 g/L) 5 days after challenge; and BEE: challenged with *E. coli* O78 and treated with BEE in drinking water 0.15 g/ liter for 5 days after challenge.

Table 4. Effect of CuO-NPs and black elderberry extract on the biochemical parameters of *E. coli* challenged SPF chicks.

Experimental Group*	NC	PC	CNP	BEE
GPT (U/l)	23.67±0.33 ^{bc}	26.67±1.33 ^{ab}	29.00±0.57 ^a	22.67±0.33 ^c
GOT (U/l)	165.67±3.38 ^b	190.00±2.31 ^a	191.33±2.96 ^a	160.67±3.48 ^b
Uric acid (mg/dl)	4.59±0.20 ^c	6.01±0.34 ^b	7.73±0.04 ^a	4.43±0.35 ^c
Creatinine (mg/dl)	0.38±0.00 ^a	0.38±0.02 ^a	0.36±0.01 ^a	0.38±0.01 ^a

Tukey's test represents the least profound differences between different groups at probability $p < 0.05$. Means with different superscripts (^{a, b, c, and d}) within a column are profoundly different at $p < 0.05$. Values are given as the mean ($n = 5$) ±SE.

*NC: non-treated non-challenged group; PC: Challenged with *E. coli* O78; CNP: challenged with *E. coli* O78 and treated with CuO-NPs in drinking water (1 g/L) 5 days after challenge; and BEE: challenged with *E. coli* O78 and treated with BEE in drinking water 0.15 g/ liter for 5 days after challenge.

The birds that received treatment in either the CNP or BEE groups showed a profound ($p < 0.05$) decline in the extent of histological damage observed within their visceral organs, as compared to the PC group. In the CNP group, the intestinal tissue exhibited a low score of 2.67 ± 0.33 , indicating the presence of moderate enteritis that marked by a limited number of infiltrations of inflammatory cells. In a similar vein, the liver tissue of the CNP group obtained a mean score of 2.33 ± 0.33 , indicating the presence of mild hepatitis represented by a few focal aggregations of inflammatory cells and minor congestion in the hepatic sinusoids. In addition, the lungs exhibited a moderate pneumonia marked by congestion of a limited number of alveolar capillaries. The corresponding score for this condition in the CNP group was recorded lower as 2.00 ± 0.00 . Within the BEE group, the histopathological examination and lesion scoring of liver, intestine and lungs revealed non-significant changes in compared with the NC.

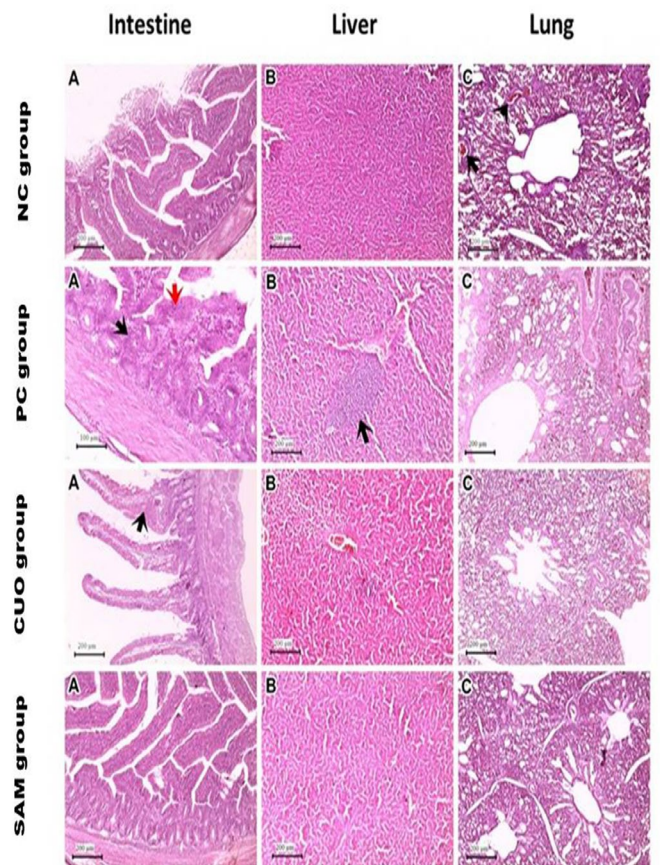


Fig. 2. Histopathological changes in visceral organs of *E. coli* challenged SPF chicks. Histopathology of visceral organs showed 1st row, (A) negative control showing mild enteritis, (B) normal liver structure, (C) mild pneumonia (black arrow). The 2nd row, (A) positive control showing severe enteritis (red and black arrows), (B) hepatic focal lymphocytic aggregations (black arrow), (C) severe pneumonia. The 3rd row G3 CNP (A) showing mild enteritis (black arrow), (B) normal liver structure, (C) mild pneumonia. The 4th row G4 BEE showing (A) mild enteritis, (B) mild hepatic congestion, (C) mild alveolar congestion.

No observable ($p > 0.05$) changes regarding to creatinine levels in all experimental groups. Although the levels of uric acid and GOT increased significantly ($p < 0.05$) in the PC group (6.01 ± 0.34 and 190.00 ± 2.31 , respectively) in comparison with the NC group (Table 4), while the BEE group recorded significantly ($p < 0.05$) lower levels of GOT (160.67 ± 3.48), and uric acid (4.43 ± 0.35) compared to the PC group but close to the values reported in the NC group. In the other side, the values of uric acid increased drastically ($p < 0.05$) in the treated group with CuO-NPs (7.73 ± 0.04) compared to the levels recorded in PC group. Moreover, no profound changes in the GPT and GOT levels between the CNP and PC groups.

Discussion

Colibacillosis is a significant cause of illness and mortality in chickens, leading to substantial economic losses in the poultry industry. The indiscriminate use of antibiotics to combat poultry pathogens has resulted in the emergence of antimicrobial resistance in *E. coli*, leading to treatment failures. The increasing prevalence of antibiotic-resistant *E. coli* strains further complicates treatment efforts, necessitating the exploration of alternative therapeutic modalities (Masood et al., 2021). This study comprehensively evaluated the therapeutic potential of copper oxide nanoparticles (CuO-NPs) and black elderberry extract against *E. coli* O78 infection in chickens.

In this study, the prepared CuO-NPs had an average crystallite size of around 12 nm, as calculated using the Scherrer equation (Scherrer, 2013). Nano-crystalline character of CuO-NPs is shown by the existence of sharp peaks and crystallite sizes less than 100 nm (Schladt et al., 2011) that often exhibit size-dependent bioactivity, and this controlled synthesis allowed us to produce uniformly dispersed particles with enhanced antibacterial effects (Rubilar et al., 2013).

The *E. coli* infection in this study showed negative drawbacks on the challenged birds represented in body weight loss, respiratory and digestive illness signs, high lesion scoring of internal organs, high relative liver

weight, presence of *E. coli* O78 with high counts in lungs and disruption in the liver and kidney functions (Tables 1-4), aligning with other reports of Elnagar et al. (2021); and Pham et al. (2023). The recorded clinical damage could be explained by the ability of *E. coli* to attach and invade the respiratory tract epithelium and then its replication causing the production of endotoxins as well as damaging to intact tissue (Srinivasan et al., 2014). Subsequently, it invades the circulatory system, spreads throughout the vital bodily organs, and induces substantial harm and lesions (Pham et al., 2023). The kidney lesions identified in the present investigation may potentially be attributed to vascular damage produced by the *E. coli* endotoxin, as suggested by Srinivasan et al. (2014). Furthermore, prior studies conducted by Abd El-Ghany and Ismail (2014); Tabatabaei et al., (2015) have reported significant detrimental changes in blood biochemical markers of the liver and kidneys as a result of *E. coli* infection. The observed results may be explained to the occurrence of hepatocellular and renal impairment during the process of detoxifying *E. coli* bacterial toxins (Srinivasan et al., 2014).

Treatment with the CuO-NPs had a significant ($p < 0.05$) positive effect on alleviating the negative impacts of *E. coli* challenge on the liver and heart lesion scoring when compared to the PC group. Also, it helped in keeping the liver relative weight near the value recorded in the NC and significantly ($p < 0.05$) lower than the PC group. CuO-NPs has succeeded in reducing the microbial load of *E. coli* in the lungs of challenged birds. In contrast, the challenged treated birds with CuO-NPs showed significant ($p < 0.05$) high levels of GOT, GPT and uric acid compared to NC and BEE groups, and this could be the root cause for high kidney scoring in the CNP group. The antibacterial effect of copper-based nanocomposite was reported against *Pseudomonas* spp. in processed food (Longano et al., 2012), and *E. coli* when loaded in cotton fabrics (Bajpai et al., 2012). Moreover, the use of CuO-NPs at a size of 50 nm in vitro showed antibacterial activity against salmonella and *Campylobacter* spp. isolated from poultry (Duffy et al., 2018). These results could be attributed to the distinct physicochemical properties of CuO-NPs which can facilitate with the lipopolysaccharide membrane of *E. coli* through electrostatic attraction between the nanoparticles' positive surface charge and the bacterial cell surface's negative charge (Nikolova and Chavali, 2020). This disrupted membrane integrity, increasing permeability and facilitating nanoparticle penetration into cells, eventually impeding metabolic processes and causing leakage of intracellular contents (Dizaj et al., 2014). Hence reducing the number *E. coli* colonizing and invading the bloodstream to visceral organs of the challenged birds.

Regarding the therapeutic efficacy of BEE against *E. coli* O78 challenge in chicks, the treatment showed significant ($p < 0.05$) lowering of internal organs lesion scoring when compared to the PC group. Moreover, it helped in keeping the liver relative weight near the value recorded in the NC and significantly ($p < 0.05$) lower than the PC group. BEE has succeeded in reducing the microbial load of *E. coli* in the lungs of challenged birds. Furthermore, there was a reduction in GPT, GOT, and uric acid in the serum of challenged treated birds. The previous researches have provided evidence of the antibacterial efficacy of black elderberry extracts against several Gram-positive and Gram-negative bacterial strains belonging to the following taxa; *Staphylococcus*, *Pseudomonas*, *Enterococcus*, *Escherichia*, *Streptococcus*, *Klebsiella*, *Bacillus*, *Corynebacterium*, and *Proteus* (Mohammadsadeghi et al., 2013; Przybylska-Balcerek et al., 2021; Haş et al., 2023). The beneficial efficacy of elderberry extract could be attributed to the existence of phenolic constituents such as anthocyanins, flavonoids, phenolic acids, polyphenols, and proanthocyanins, which have a significant antioxidant effect, remove free radicals and combat oxidative stress, anti-inflammatory and antibacterial activities (Kashi et al., 2019; Pascuta and Vodnar, 2022). Moreover, data from the specialized literature attributed the antimicrobial effect to tannins and triterpenes, as well as to peptides and oligosaccharides that are present in black elderberry (Hearst et al., 2010). Furthermore, it stimulated the production of pro-inflammatory cytokines IL-1b, IL-6, IL-8, and tumor necrosis factor TNF- α , as well as anti-inflammatory cytokine IL-10 by macrophages collected from humans (Gramza-Michałowska et al., 2017). The documented potent immune-modulating agents in elderberry extract as anthocyanins, phenolic acids, and flavonoids, enable the extract to boost immunity against protozoa, parasites, gram-positive bacteria, gram-negative bacteria, and viruses (Khan et al., 2022).

Notably, early intervention with either CuO-NPs or BEE post-infection inhibited *E. coli* colonization reduced associated clinical manifestations, decreased pathological organ changes, and improved liver and kidney function compared to infected non-treated chicks. This underscores their therapeutic potential in clinical colibacillosis. However, the CNP group exhibited a spike in uric acid levels, which warrants further safety evaluation. BEE showed slightly greater efficacy overall, possibly due to its synergistic antibacterial and immuno-protected mechanisms. Further studies should aim to decipher their molecular mechanisms of action against *E. coli* using omics-based approaches. Dose-optimization and pharmacokinetic char-

acterization are also needed to translate these findings into clinical applications. Investigating combination therapy with both nanoparticles and phytochemicals could provide synergistic benefits against colibacillosis.

Conclusion

This study demonstrates the promising efficacy of CuO-NPs and BEE against *E. coli* O78 infection in SPF chicks. Both modalities reduced clinical morbidity, bacterial load, and clinicopathological changes by exploiting their intrinsic antimicrobial and immunomodulatory properties. These findings provide a framework for developing nanoparticle and plant-derived regimens to combat colibacillosis and mitigate antibiotic resistance. Further optimization and mechanistic studies in additional animal models are warranted to support their clinical translation. Overall, this work highlights the potential of bio-based therapeutic approaches for improving poultry health and treatment outcomes and reducing the environmental footprint of antibiotic overuse.

Conflict of interest

The authors declare that they have no conflict of interest.

References

- Abd El-Ghany, W.A., Ismail, M., 2014. Tackling experimental colisepticaemia in broiler chickens using phytochemical essential oils and antibiotic alone or in combination. *Iran. J. Vet. Res.* 15, 110–115.
- Allocati, N., Masulli, M., Alexeyev, M.F., Di Ilio, C., 2013. *Escherichia coli* in Europe: An overview. *Inter. J. Environ. Res. Public Health* 10, 6235–6254.
- Ateya, A.I., Arafat, N., Saleh, R.M., Ghanem, H.M., Naguib, D., Radwan, H.A., Elseady, Y.Y., 2019. Intestinal gene expressions in broiler chickens infected with *Escherichia coli* and dietary supplemented with probiotic, acidifier and synbiotic. *Vet. Res. Commun.* 43, 131–142.
- Bajpai, S.K., Bajpai, M., Sharma, L., 2012. Copper nanoparticles loaded alginate-impregnated cotton fabric with antibacterial properties. *J. Appl. Polymer Sci.* 126.
- Bancroft, J.D., Gamble, M., 2008. *Theory and Practice of Histological Techniques*. 6th Edition, Churchill Livingstone, Elsevier, China. - References - Scientific Research Publishing.
- Chodkowska, K.A., Iwiński, H., Wódz, K., Nowak, T., Różański, H., 2022. In Vitro Assessment of Antimicrobial Activity of Phytochemicals Composition towards of Avian Pathogenic *Escherichia coli* (APEC) and Other *E. coli* Strains Isolated from Broiler Chickens. *Antibiotics* 11, 1818.
- Dizaj, S.M., Lotfi-pour, F., Barzegar-Jalali, M., Zarrintan, M.H., Adibkia, K., 2014. Antimicrobial activity of the metals and metal oxide nanoparticles. *Mater. Sci. Engineer. C* 44, 278–284.
- Duffy, L.L., Osmond-McLeod, M.J., Judy, J., King, T., 2018. Investigation into the antibacterial activity of silver, zinc oxide and copper oxide nanoparticles against poultry-relevant isolates of *Salmonella* and *Campylobacter*. *Food Control* 92, 293–300.
- El-Boushy, M.E., Sanaa, S.A., Abeer, H., 2006. Immunological, hematological and biochemical studies on pefloxacin in broilers infected with *E. coli*. In *Proceedings of the 8th Sciences Veterinary Medicine Zagazig Conference*, pp. 55–59.
- Elmowalid, G.A., Abd El-Hamid, M.I., Abd El-Wahab, A.M., Atta, M., Abd El-Naser, G., Attia, A.M., 2019. Garlic and ginger extracts modulated broiler chicks innate immune responses and enhanced multidrug resistant *Escherichia coli* O78 clearance. *Comparative Immunology, Microbiol. Infect. Dis.* 66, 101334.
- Elnagar, R., Elkhenany, R., Younis, G., 2021. Interleukin gene expression in broiler chickens infected by different *Escherichia coli* serotypes. *Vet. World* 14, 2727–2734.
- Gibson-Corley, K.N., Olivier, A.K., Meyerholz, D.K., 2013. Principles for Valid Histopathologic Scoring in Research. *Vet. Pathol.* 50, 1007–1015.
- Goren, E., 1978. Observations on experimental infection of chicks with *Escherichia coli*. *Avian Pathol.* 7, 213–224.
- Gramza-Michałowska, A., Sidor, A., Kulczyński, B., 2017. Berries as a potential anti-influenza factor—A review. *J. Funct. Foods*, 37, 116–137.
- Hammerum, A.M., Heuer, O.E., 2009. Human health hazards from antimicrobial-resistant *Escherichia coli* of animal origin. *Clin. Infect. Dis.*, 48, 916–921.
- Haş, I.M., Teley, B.-E., Szabo, K., Simon, E., Ranga, F., Diaconeasa, Z.M., Purza, A.L., Vodnar, D., Tit, D.M., Nițescu, M., 2023. Bioactive Potential of Elderberry (*Sambucus nigra* L.): Antioxidant, Antimicrobial Activity, Bioaccessibility and Prebiotic Potential. *Molecules* 28, 3099.
- Hashem, M.A., Neamat-Allah, A.N.F., Hammza, H.E.E., Abou-Elnaga, H.M., 2020. Impact of dietary supplementation with *Echinacea purpurea* on growth performance, immunological, biochemical, and pathological findings in broiler chickens infected by pathogenic *E. coli*. *Trop. Anim. Health Prod.* 52, 1599–1607.
- Hearst, C., Mccollum, G., Nelson, D., Ballard, L.M., Millar, B.C., Goldsmith, C.E., Rooney, P.J., Loughrey, A., Moore, J.E., Rao, J.R. 2010. Antibacterial activity of elder (*Sambucus nigra* L.) flower or berry against hospital pathogens. *J. Med. Plants Res.* 4, 1805–1809.
- Jamil, B., Abbasi, R., Abbasi, S., Imran, M., Khan, S. U., Ihsan, A., Javed, S., Bokhari, H., 2016. Encapsulation of cardamom essential oil in chitosan nano-composites: In-vitro efficacy on antibiotic-resistant bacterial pathogens and cytotoxicity studies. *Front. Microbiol.* 7, 1–10.
- Kashi, D.S., Shabir, A., Da Boit, M., Bailey, S.J., Higgins, M.F., 2019. The Efficacy of Administering Fruit-Derived Polyphenols to Improve Health Biomarkers, Exercise Performance and Related Physiological Responses. *Nutrients*, 11, 2389.
- Khan, A., Rashid, A., Younas, R., Chong, R. 2016. A chemical reduction approach to the synthesis of copper nanoparticles. *Inter. Nano Lett.*, 6, 21–26.
- Khan, M.M., Murtuza, A., Ibrahim, M., Mustafa, A., 2022. Assessment of the role of anthocyanin standardized elderberry (*Sambucus nigra*) extract as an immune-stimulating nutraceutical of Nile tilapia, *Oreochromis niloticus*. *PLOS ONE* 17, e0279471.
- Longano, D., Ditaranto, N., Cioffi, N., Di Niso, F., Sibillano, T., Ancona, A., Conte, A., Del Nobile, M. A., Sabbatini, L., Torsi, L., 2012. Analytical characterization of laser-generated copper nanoparticles for antibacterial composite food packaging. *Anal. Bioanal. Chem.* 403, 1179–1186.
- Masood, K., Yasmin, H., Batool, S., Ilyas, N., Nosheen, A., Naz, R., Khan, N., Nadeem Hassan, M., Aldhahrani, A., Althobaiti, F., 2021. A strategy for mitigating avian colibacillosis disease using plant growth promoting rhizobacteria and green synthesized zinc oxide nanoparticles. *Saudi J. Biol. Sci.* 28, 4957–4968.
- Melesse, A., Maak, S., Schmidt, R., Von Lengerken, G., 2011. Effect of long-term heat stress on some performance traits and plasma enzyme activities in Naked-neck chickens and their F1 crosses with commercial layer breeds. *Livestock Sci.* 141, 227–231.
- Mellata, M., 2013. Human and Avian Extraintestinal Pathogenic *Escherichia coli*: Infections, Zoonotic Risks, and Antibiotic Resistance Trends. *Foodborne Pathog. Dis.* 10, 916–932.
- Młynarczyk, K., Walkowiak-Tomczak, D., Łysiak, G.P., 2018. Bioactive properties of *Sambucus nigra* L. as a functional ingredient for food and pharmaceutical industry. *J. Funct. Foods* 40,

- 377–390.
- Mohammadsadeghi, S., Malekpour, A., Zahedi, S., Eskandari, F., 2013. The antimicrobial activity of elderberry (*Sambucus nigra* L.) extract against gram positive bacteria, gram negative bacteria and yeast. Res. J. Appl. Sci. 8, 240–243.
- Najmi, A., Javed, S.A., Al Bratty, M., Alhazmi, H.A., 2022. Modern Approaches in the Discovery and Development of Plant-Based Natural Products and Their Analogues as Potential Therapeutic Agents. Molecules 27, 349.
- Nikolova, M.P., Chavali, M.S., 2020. Metal Oxide Nanoparticles as Biomedical Materials. Biometrics 5, 27.
- Pascuta, M., Vodnar, D., 2022. Nanocarriers for Sustainable Active Packaging: An Overview during and Post COVID-19. Coatings 12, 102.
- Pham, V.H., Abbas, W., Huang, J., Guo, F., Zhang, K., Kong, L., Zhen, W., Guo, Y., Wang, Z., 2023. Dietary coated essential oil and organic acid mixture supplementation improves health of broilers infected with avian pathogenic *Escherichia coli*. Animal Nutr. 12, 245–262.
- Przybylska-Balcerek, A., Szablewski, T., Szwajkowska-Michalek, L., Świerk, D., Cegielska-Radziejewska, R., Krejpcio, Z., Suchowilska, E., Tomczyk, Ł., Stuper-Szablewska, K., 2021. *Sambucus nigra* Extracts—Natural Antioxidants and Antimicrobial Compounds. Molecules 26, 2910.
- Rubilar, O., Rai, M., Tortella, G., Diez, M.C., Seabra, A.B., Durán, N., 2013. Biogenic nanoparticles: Copper, copper oxides, copper sulphides, complex copper nanostructures and their applications. Biotechnol. Lett. 35, 1365–1375.
- Sánchez-López, E., Gomes, D., Esteruelas, G., Bonilla, L., Lopez-Machado, A.L., Galindo, R., Cano, A., Espina, M., Ettchetto, M., Camins, A., Silva, A.M., Durazzo, A., Santini, A., Garcia, M.L., Souto, E.B., 2020. Metal-based nanoparticles as antimicrobial agents: An overview. Nanomater. 10, 1–39.
- Scherrer, P., 2013. Estimation of the size and internal structure of colloidal particles by means of röntgen. South Afri. J. Sci. 109, 96–100.
- Schladt, T., Schneider, K., Schild, H., Tremel, W., 2011. Synthesis and bio-functionalization of magnetic nanoparticles for medical diagnosis and treatment. Dalton Transct. 40, 6315–6343.
- Sharif, M., Rahman, M.A., Ahmed, B., Abbas, R.Z., Hassan, F., 2021. Copper Nanoparticles as Growth Promoter, Antioxidant and Anti-Bacterial Agents in Poultry Nutrition: Prospects and Future Implications. Biol. Trace Elem. Res. 199, 3825–3836.
- Srinivasan, P., Balasubramaniam, G.A., Murthy, T.R.G.K., Balachandran, P., 2014. Pathomorphological studies of polyserositis in commercial caged layer chicken. Asian Pacific J. Trop. Med. 7, S313–S320.
- Tabatabaei, S.M., Badalzadeh, R., Mohammadnezhad, G.R., Balaei, R., 2015. Effects of Cinnamon extract on biochemical enzymes, TNF- α and NF- κ B gene expression levels in liver of broiler chickens inoculated with *Escherichia coli*. Pesquisa Veterinaria Brasileira 35, 781–787.
- Tovar, D., Zambonino, J., Cahu, C., Gatesoupe, F., Vázquez-Juárez, R., Lésel, R., 2002. Effect of live yeast incorporation in compound diet on digestive enzyme activity in sea bass (*Dicentrarchus labrax*) larvae. Aquaculture 204, 113–123.
- Wang, S., Peng, Q., Jia, H.M., Zeng, X. F., Zhu, J. L., Hou, C.L., Liu, X.T., Yang, F.J., Qiao, S.Y., 2017. Prevention of *Escherichia coli* infection in broiler chickens with *Lactobacillus plantarum* B1. Poultry Sci. 96, 2576–2586.
- Wang, Y., Yang, Y., Shi, Y., Song, H., Yu, C., 2020. Antibiotic-Free Antibacterial Strategies Enabled by Nanomaterials: Progress and Perspectives. Adv. Mater. 32, 18.